

Automated CAD System for Early Stroke Diagnosis: Review

Izzatul Husna Azman¹, Norhashimah Mohd Saad², Abdul Rahim Abdullah³,
Rostam Affendi Hamzah⁴, Adam Samsudin⁵, Shaarmila A/P Kandaya⁶

Faculty of Electrical Engineering, Universiti Teknikal Malaysia Melaka, Malaysia^{1,3,6}

Faculty of Electrical and Electronic Engineering Technology, Universiti Teknikal Malaysia Melaka, Malaysia^{2,4,5}

Abstract—Stroke is an important health issue that affects millions of people globally each year. Early and precise stroke diagnosis is crucial for efficient treatment and better patient outcomes. Traditional stroke detection procedures, such as manual visual evaluation of clinical data, can be time-consuming and error-prone. Computer-aided diagnostic (CAD) technologies have emerged as a viable option for early stroke diagnosis in recent years. These systems analyze medical pictures, such as magnetic resonance imaging (MRI), and identify indicators of stroke using modern algorithms and machine learning approaches. The goal of this review paper is to offer a thorough overview of the current state-of-the-art in CAD systems for early stroke detection. We give an examination of the merits and limits of this technology, as well as future research and development directions in this field. Finally, we contend that CAD systems represent a promising solution for improving the efficiency and accuracy of early stroke diagnosis, resulting in better patient outcomes and lower healthcare costs.

Keywords—Stroke diagnosis; CAD system; machine learning; deep learning

I. INTRODUCTION

Stroke, also known as cerebrovascular illness, is the third highest cause of death in Malaysia. In 2019, there were 47,928 fatalities, 443,995 common cases, and 512,726 DALYs lost due to stroke. [1] According to a White Paper on Acute Stroke Care in Malaysia by the Galen Centre for Social Health and Policy, commissioned and funded by Boehringer Ingelheim (Malaysia), only 21% of stroke patients were able to be treated at a medical facility within three hours of the onset of symptoms, while the median time from the onset of stroke symptoms to arrival at a hospital was seven hours or more [2]. Stroke is a disease that arises when an artery or blood vessel becomes clogged or ruptured, resulting in decreased blood flow and oxygen delivery to the brain which leads to temporary or permanent failure in humans; an untreated stroke can result in death [3]. Strokes are classified into two types: ischemic and hemorrhagic as shown in Fig. 1. Ischemic strokes are caused by artery blockages or occlusions caused by plaque build-up along the inner lining of the arteries. This kind of stroke occurs in more than 80% of cases, typically abruptly and without warning. Hemiparesis is the most common symptom of an ischemic stroke, which occurs when one side of the body suddenly becomes weak or unable to move. Hemorrhagic stroke is caused mostly by the rupture of cerebral blood vessels, aneurysms, or physical trauma. More than half of people who survive this type of stroke will have a serious

disability. Both the effects of a stroke and the recovery process are particular to each individual. However, only 107 neuroradiologists were supposedly available to treat patients, with at least one of them in every state hospital in our country where it is very critical and limited. Also, the traditional method of analyzing clinical data for stroke diagnosis involves manual visual inspection, which is a time-consuming process. Unfortunately, delayed stroke diagnosis and treatment can lead to brain cell death, as individuals become disabled due to a lack of oxygen and blood flow.

Technological developments in healthcare have led to various enhancements in disease diagnostics. Medical Imaging, which includes Cone Beam Computed Tomography (CBCT), Computed Tomography (CT), and Magnetic Resonance Imaging (MRI), is one of them. This technology is capable of producing specific images of a particular area based on the imaging techniques used. To diagnose stroke patients, radiologists use CT and MRI scans. However, detecting irregularities in the images can be challenging since recent research has shown that the patient's life can potentially be saved if treatment is initiated within the first six hours of a stroke. This period is referred to as the "Golden hours." [4] MRI is a medical imaging technology that employs a powerful magnet, radio waves, and computer to create highly detailed images without the use of radiation. According to Nouf Saeed Alotaibi's research in 2022, MRI is currently the most precise imaging test for brain medical imaging when compared to other technologies like CT scans or X-rays. Magnetic resonance imaging (MRI) is increasingly being used in the diagnosis and treatment of acute ischemic stroke due to its high sensitivity and relatively high specificity in detecting abnormalities that occur after such strokes [5]. The MRI process involves using T1, T2, Flair, DWI, and Black Blood sequences to gather data that must be obtained within 6 hours after the stroke that referred to as the "golden hour of stroke."

Some researchers have developed computer-aided diagnosis (CAD) systems for MRI to address the limitations of manual visual inspection for stroke diagnosis. These systems analyze MRI images using algorithms and machine learning approaches to detect anomalies associated with acute ischemic stroke. CAD systems can save time and minimize the strain on neuroradiologists by automating the analysis procedure. Furthermore, CAD systems may improve the accuracy of stroke diagnosis, resulting in earlier treatment and better patient outcomes. CAD systems for MRI stroke diagnosis are often divided into phases. MRI images are first pre-processed

to reduce noise and artefacts. Following that, feature extraction techniques are used to identify key image characteristics associated with strokes. Finally, a machine learning system is trained on a collection of MRI pictures with established stroke diagnoses to identify fresh images as normal or suggestive of acute ischemic stroke. Recent research has demonstrated that CAD systems can detect acute ischemic stroke in MRI images with great accuracy. In one study, for example, a CAD system was shown to have a sensitivity of 93% and a specificity of 95% in diagnosing acute ischemic stroke in brain MRI data. Another study discovered that a CAD system could distinguish between acute and chronic ischemic strokes with 95% accuracy. Overall, CAD systems for MRI stroke diagnosis have the potential to increase the efficiency and accuracy of stroke diagnosis, thereby shortening treatment time.

In conclusion, in the past few years, CAD systems have demonstrated great potential in enhancing the speed and precision of stroke diagnosis as well as enabling prompt and efficient treatment. This review paper aims to present a thorough summary of the latest diagnosis methods and system algorithms in CAD systems, with the goal of achieving early stroke detection. The purpose of this paper is to examine the application of these systems in modern stroke treatment research and showcase the latest developments in this area. Furthermore, this review will delve into the advantages and disadvantages of CAD systems and investigate the obstacles and prospects for additional research and enhancement. And lastly, our hope is to contribute to global efforts to enhance stroke diagnosis and treatment by conducting a critical assessment of the latest advancements in CAD systems for the early detection of stroke.

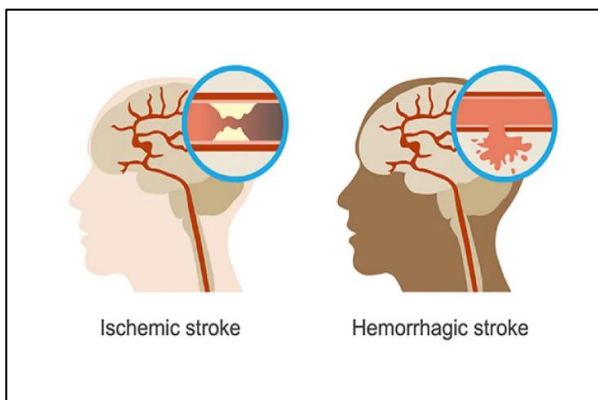


Fig. 1. Comparison of Ischemic and Hemorrhagic stroke [4].

II. MEDICAL IMAGING MODALITY FOR STROKE DIAGNOSIS

Modern advancements have resulted in a variety of methods for treating and diagnosing early stroke. These include a variety of approaches for diagnosis and assessment that doctors can use to provide the best therapy possible depending on the patient's medical history. The first step in diagnosing a stroke patient is determining if the patient is suffering from an ischemic or hemorrhagic stroke so that appropriate therapy may begin. The initial test is a CT scan or an MRI of the head for the early diagnosis of stroke.

A. Magnetic Resonance Imaging (MRI)

MRI has been the primary neuroimaging modality in several specialized clinics for critical-stage stroke in recent years, allowing pathophysiological evaluation of critical-stage stroke. In the brain, MRI can differentiate between white matter and grey matter and can also be used to diagnose aneurysms and tumours [3] [5]. MRI is the preferred imaging modality for diagnosis and therapy in the brain. Due to its sensitivity, accuracy, extension, and age, MRI is the most instructive imaging technique. Besides DWI and SWI, one of the sequences that latest in MRI is BB sequence (Black Blood Sequence) compared to conventional sequence: T1, T2 and Flair. Apart from DWI and SWI, one of the most recent MRI sequences for stroke is the BB sequence (Black Blood Sequence), as opposed to the conventional sequences: T1, T2, and Flair. Fig. 2 shows a comparison of brain lesions in BB sequence with CE T1, where study shows that BB-based automatic detection is more sensitive than MP-RAGE of CE T1 and has greater potential benefits in terms of automated CNN-based detection. MRI black blood imaging (BB) suppresses intraluminal blood signal throughout the field of view without reducing the signal strength of tiny abnormal region or lesion, allowing human readers to detect brain lesions [6]. Fig. 2 shows the comparison of the same lesion in different modalities; BB sequence and CE-T1 sequence of MRI.

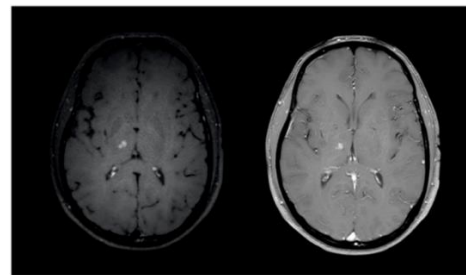


Fig. 2. Left, lesion in the Black Blood sequence (BB). Right, corresponding axial conventional Contrast-Enhance T1 slice with identical lesion. [6].

B. Computed Tomography (CT)

A CT scan is a diagnostic imaging process that produces pictures of the interior of the body using X-rays and computer technologies. It displays comprehensive views of every bodily component, including the bones, muscles, fat, organs, and blood vessels. The X-ray beam in CT moves in a circle around the body. This allows for many views of the same organ or structure and gives far more information. Hence, CT is the most effective imaging modality for acute ischemic stroke because of its availability, low cost, and quick acquisition time [7, 8]. CT also act as a standard in the early examination of acute stroke patients because it can readily and quickly see cerebral hemorrhages (as shown in Fig. 3) [9]. Dynamic contrast-enhanced (DCE)-CT is also utilized in clinical practice to improve image resolution and to examine the microvasculature of brain structures and other organs. In DCE-CT imaging, an iodine-based contrast agent is administered intravenously into the patient's body, affecting the measured X-ray absorption in tissues, and leading in contrast enhancement in the produced picture. At last in this section, Fig. 4 illustrated the three different samples of modalities including CT, Flair and DWI of MRI images.

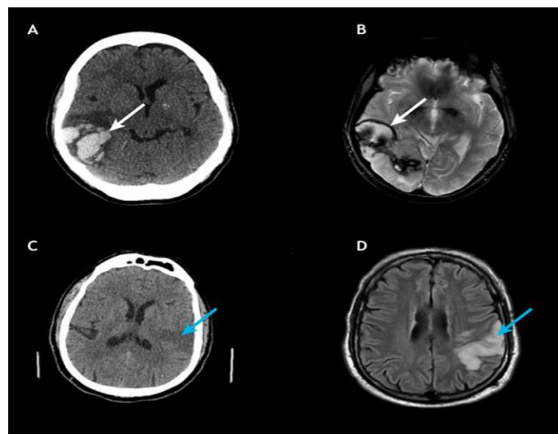


Fig. 3. CT scans against MRI scans for stroke detection. (A, B) A hemorrhage may be plainly observed in a patient's CT scan (A; white arrow), although it is less visible in an MRI scan (B; white arrow). (C, D) An ischemic infarct is just faintly visible in a C. [9].

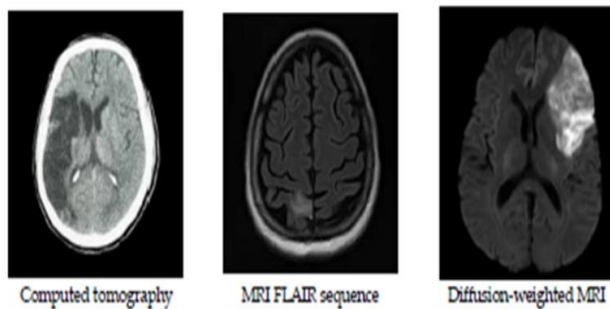


Fig. 4. Sample of CT images, MRI Flair and DWI sequences images [10].

III. STROKE DIAGNOSIS SYSTEM

Modern stroke detection devices, such as computed tomography (CT) and magnetic resonance imaging (MRI), may aid an experienced radiologist in determining if a patient has suffered a stroke; however, if a general radiologist makes an incorrect diagnosis, the patient may miss the best time for treatment. As a result, improving the quality of the diagnostic picture is crucial for assisting the physician in making an accurate diagnosis or image identification. In terms of stroke risks, different computer-aided diagnostic (CAD) systems have been created to help physicians diagnose and treat stroke patients. These methods enabled the identification of early cerebrovascular accident (CVA) symptoms and contributed to increased diagnosis accuracy for acute strokes. A notable trend is machine learning research and end-to-end system design for computer-aided stroke diagnosis and classification. Hence, there are already some important papers and developed systems for the binary classification of stroke presence or absence and hemorrhagic or ischemic stroke [11].

A. Computer-aided Diagnosis System (CAD)

The CAD technique has been used in medical imaging for illness diagnosis, prognosis, treatment decision assistance, and therapeutic monitoring. Manual segmentation in MRI takes a long time because specialists must examine several pictures of the brain taken in different orientations using different pulse

sequences [10]. Moreover, there is the possibility of inter- and intra-observer biases. These limitations can be overcome by semi-automated and automated machine learning-based CAD systems for identifying and segmenting ischemic stroke lesions, enabling high-throughput image screening for faster, reproducible, and more sensitive detection of ischemic stroke lesions. The automated delineation of the precise topology of stroke lesions allows for quantitative evaluations of infarct size and/or salvage ability, which is important for prognosis and therapeutic decision-making. A typical stroke CAD system consists of distinct sequential stages as referred to in Fig. 5.

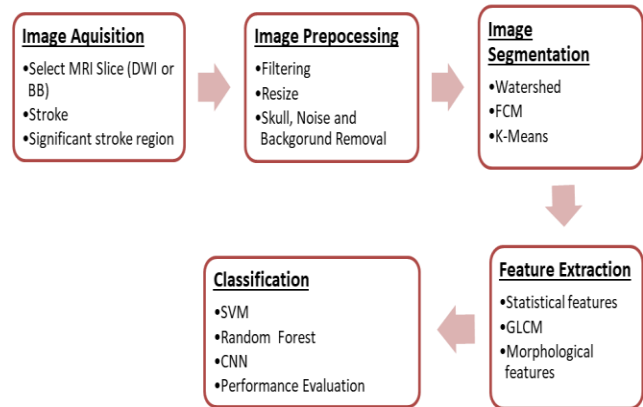


Fig. 5. Overview of typical Computer-Aided Diagnosis (CAD) system for end-to-end stroke detection.

Apart from that, several methodologies have been used to assess the performance of CAD systems in preparation for commercialization. Methods such as leave-one-out, cross-validation, hold-out, and resubstituting are examples of these techniques. The pattern recognition process in classical and current CAD medical algorithms typically consists of three major phases; however, completion of all three steps is not required. These processes are as follows: pre-processing of medical pictures, including segmentation and identification of areas of interest (ROI), extracting automatically produced or hand-engineered features from human specialists, and data categorization according to those characteristics in Fig. 5. Current CAD algorithms can offer output data without going through all of these processes; this became feasible with the development of neural networks with several hidden layers. [12]. There are also several types of processing phase in CAD as shown in Fig. 6.

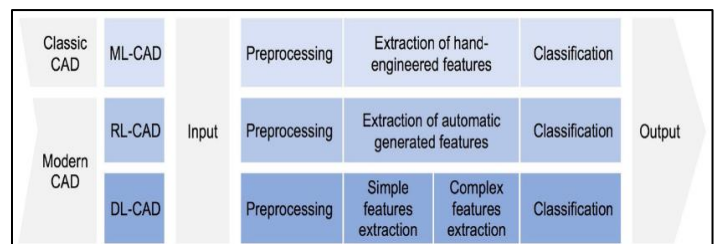


Fig. 6. Several types of processing phases in CAD including ML-CAD(Machine Learning based), RL-CAD(Representation Learning based) and DL-CAD(Dep Learning based) [12].

B. Machine Learning Technique

Watershed segmentation is a segmentation technique that uses gradients. The watershed transformation considers the size of the image's gradient as a topographic surface. The water flow line, which indicates the region's borders, corresponds to pixels with the maximum gradient magnitude intensity (GMI). Water is placed on any pixel that is surrounded by flowing stream water that flows naturally down to the minimal local average intensity. Pixels flow into the same shape as the segment's catchment basin. The watershed transform has a severe disadvantage in that it has a propensity to over-segment the picture. To evade this constraint, the object's position must be inferred using instance markers, which can guide the selection of a subset of these basins. [13]

Fuzzy C-Means (FCM) is an excellent data analysis, pattern recognition, picture segmentation, and fuzzy modelling algorithm [13]. It is a well-known soft clustering method and one of the most promising fuzzy clustering methods. Fuzzy clustering algorithms are preferable because they can more intuitively describe the link between input pattern data and clusters [14]. It is more flexible than the analogous hard-clustering approach in most circumstances, as it uses a membership function to connect each pattern to each cluster. Clustering, but not partitioning, is the result of such algorithms. A hybrid technique involving the K-means and FCM algorithms was proposed, which enhanced the accuracy in diagnosing brain infarct with lower processing costs (Fig. 7 to 9 [10]).

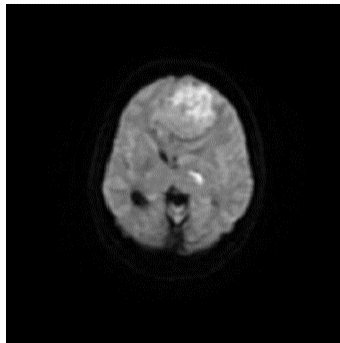


Fig. 7. Original DWI sample image.




Fig. 8. Morphological binary image from sample image in Fig. 7.

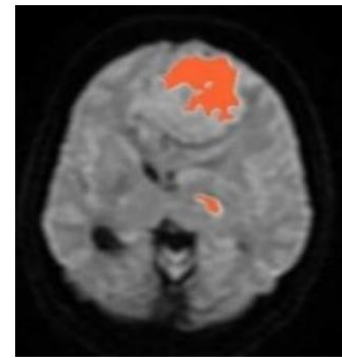


Fig. 9. Orange marking on detected infarct.

The K-Means algorithm is a clustering approach that is used to identify the optimal answer by continually decreasing the distance of components from their cluster centre and increasing the cluster. Since the k-performance algorithm is reliant on the beginning value of the cluster centre, strategies must be tested numerous times for varied results with different initial cluster centres [15]. The primary drawbacks of this approach are that the number of clusters is unexpected and that it is sensitive to the initial cluster centres. To circumvent this constraint, a statistical calculation or cluster verification approach is necessary [13]. Hence, the overview comparison in pros and cons of these 3 techniques are shown in Table I.

TABLE I. OVERVIEW COMPARISON SEGMENTATION TECHNIQUES (FCM, K-MEANS, WATERSHED) [10] [14] [15]

Segmentation Technique	Advantages	Disadvantages
Watershed Transform [10]	Several areas are segmented at the same time. It produces a complete contour of the images and avoids the need for many contours to be joined.	Over segmentation could be easily obtained.
Fuzzy C-Means [14]	Defines a distinct border for the split region.	Sensitive to noise.
k-Means [15]	If k is kept small, it is faster to compute than hierarchical clustering.	The exact number of clusters is unknown.

As for image classification in medical imaging, especially for stroke, Support Vector Machines (SVM) are classified as a classification technique, whereas it can be used in both classification and regression situations. It is capable of handling a large number of continuous and categorical variables. SVM is also classified as one of the supervised learning classification techniques that builds a hyperplane (or series of hyperplanes) in a higher-dimensional space to classify. SVM iteratively develops ideal hyperplanes, which are used to minimise errors. SVM's core notion is to determine the maximum marginal hyperplane (MMH) that optimally allocates a dataset into classes, as shown in Fig. 10. SVM was utilised to appropriately identify them as benign tumours, malignant tumours, or healthy brains. Support Vector machines (SVMs) have substantial computational advantages [16].

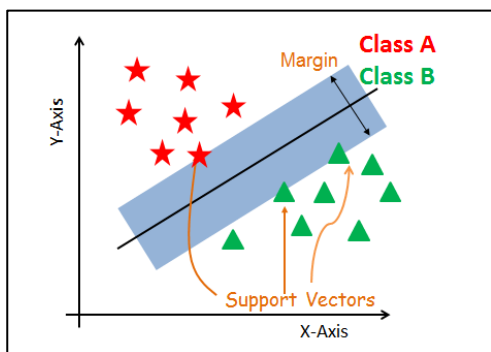


Fig. 10. Support Vector Machines techniques (SVM) [16].

Random-forest classification is a prominent supervised classification approach. Random forest classifiers are trained classifiers that are used to outline the borders of feature space points that belong to various classes, with the purpose of minimizing the margin between classes (like a SVM classifier) [17]. The random forest is made up of a few decision trees that have been trained to accept input values (feature vectors) and assign membership values to the lesion or background groups as illustrated in Fig. 11. The random forest's final predictions are formed by averaging the results of each individual tree, which tends to over fit the training data, but the random forest may reduce that issue by averaging the prediction results from multiple trees. As a result, random forests outperform single decision trees in terms of predicting validity. A study recommended that dense conditional random fields (CRF), which are frequently used as a post processing step to generate more spatially contiguous segmentations, be implemented as an optimizer in system [18]. The features used for training in RF-based multilayer cascaded RFs are still based on independent voxels and their neighbours, whereas in dense CRFs, the inference process implicitly assumes conditional independence between voxels, which may lose correlation constraints between directly adjacent voxels.

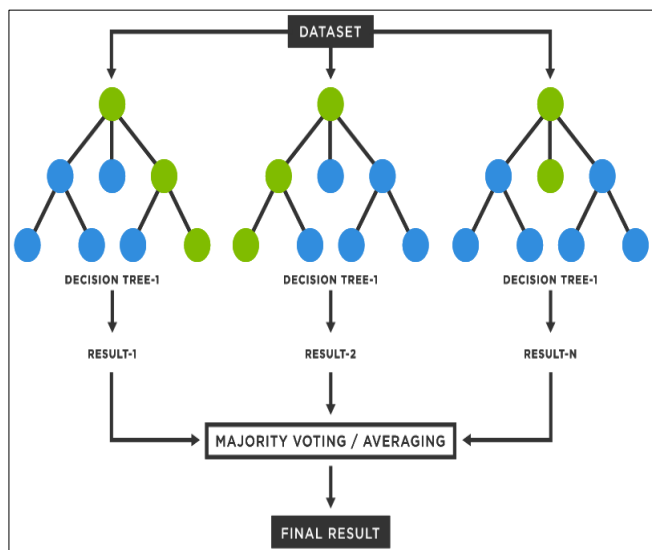


Fig. 11. Random Forest techniques (RF) [19].

C. Deep Learning Technique

Deep learning algorithms have consistently demonstrated transformative performance in a variety of tasks, most notably medical image analysis as shown in Fig. 12. Convolutional neural networks have been particularly successful in identifying and classifying patterns in medical images, leading to improved diagnosis and treatment planning. Additionally, deep learning models can also assist in predicting patient outcomes and detecting anomalies that may be missed by human observers. Convolutional neural networks are now a deep learning technique commonly used in computer vision tasks like radiography. It is designed to learn spatial information by backpropagation, utilizing numerous building blocks to achieve exceptional results in image identification. Deep learning models along with the application of CNN are being considered as methods for imaging acute ischemic strokes. Illustrated by a convolutional neural network (CNN), systematically pulls measurements from many samples in order to acquire more sophisticated abstract features for classification, recognition, and segmentation, enabling intelligent MRI interpretation [20]. It computed neural network characteristics and developed code for use in CNN input stages and passing signals with geometric detail. The visual cortex field interacts with individual cortical neurons belonging to the scanning field but does not transmit CNN weak signals. CNN nodes are linked, but not all-to-all links in a geometrical framework. In the image processing input layer, nodes are assigned to generate spectrum ranges for scanning components and shapes. All comparable structures and images (the kernel) are derived. The picture was transmitted to MRI outputs through kernel signals [7].

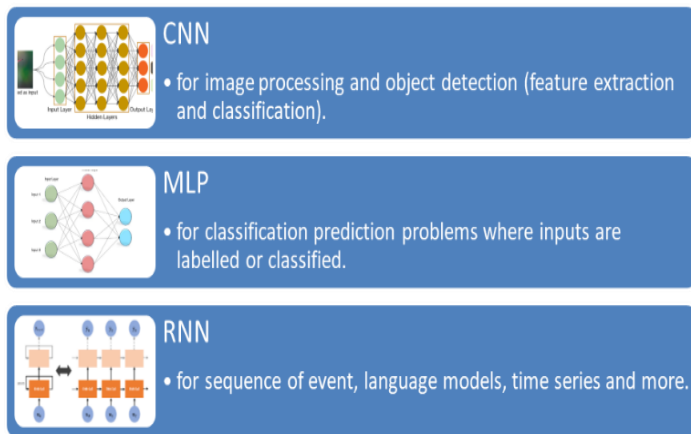


Fig. 12. Deep learning algorithm.

IV. RESULTS AND DISCUSSION

This section provides an inventory of findings from a variety of recent research initiatives that have used ML and DL approaches to construct early stroke diagnostic systems based on MRI data. We shed light on the findings of these research by thorough classification and theme analysis, uncovering recurring trends, diverse outcomes, and methodological variances as shown in Table II. The given results included a wide range of performance parameters, highlighting accomplishments in sensitivity, specificity, and diagnostic accuracy. Notably, we investigate how dataset sizes,

architectural choices, feature extraction approaches, and pre-processing procedures affect the effectiveness of these systems. We provide a panoramic picture of the state-of-the-art in ML and DL-powered stroke detection by aggregating these findings, revealing the shared discoveries that contribute to the progress of this critical medical application.

Drawing on the findings of Yannan Yu and colleagues' work, the core approach used focuses on the use of deep learning U-Net for determining Final Ischemic Stroke patients [21]. The findings of this study demonstrate a dichotomy of results, defined into two separate categories: minor instances (n = 32), with a dice score coefficient (DSC) of 0.58 (0.31-0.67), and major instances (n = 67), with a DSC of 0.67 (0.29-0.65). Furthermore, Hyuna Lee and colleagues conducted remarkable work on stroke detection, utilizing a variety of methodologies such as Logistic Regression, Support Vector Machine (SVM), and Random Forest. The findings of this comprehensive method show that Logistic Regression has a sensitivity parameter of 75.8%, while SVM and Random Forest both have a noteworthy 72.8% sensitivity [22].

Yusuf and colleagues also made significant contributions, exploring hemorrhagic and ischemic stroke using deep learning CNN approaches, especially improved MobileNetV2 and EfficientNet-B0 models. In stroke detection, the updated MobileNetV2 model obtains a remarkable accuracy of 96% (: 0.92), whereas the modified EfficientNet-B0 model achieves 93% (: 0.86). Not content with diagnosis, they expand their investigation towards vascular territorial categorization, revealing outstanding accuracy rates of 93% (0.895) using the modified MobileNetV2 model and 87% (0.805) using the modified EfficientNet-B0 CNN model [11].

Meanwhile, Sercan and colleagues focus their work on brain tumour and ischemic and hemorrhagic stroke lesion studies, using deep learning capabilities through the CNN-D-UNet architecture. Their sophisticated technique yields precision levels of 0.99 and accuracy levels of 0.989 for brain tumours, while precision and accuracy levels for brain stroke lesions are commendably documented at 0.986 and 0.985, respectively [23].

Adriell adopts a more specialised approach, concentrating just on hemorrhagic stroke segmentation using the Mask R-CNN technique and fine-tuning it to get results with a remarkable accuracy of 99.72% 0.24 and sensitivity of 99.97% 0.06 [24]. Fathia's research focuses on ischemic stroke and employs a trinity of deep learning techniques - CNN, U-Net, and Fine Tuning. Their efforts were rewarded with an average accuracy of 99.77% and a Dice Coefficient of 55.77% [25].

Finally, a notable work released in 2023 by Hongyu Gao and colleagues explores the landscape of Acute Ischemic stroke using a repertory of CNN, SVM, and Random Forest approaches. Significantly, the results highlight the CNN classifier's dominance, with an exceptional area under the curve (AUC) of 0.935, validating its usefulness in the domain [26].

TABLE II. OVERVIEW OF THE COMPARISON BASED ON RECENT RESEARCH

Author	Type of lesion	Technique used	Result parameter
Yannan Yu, 2020 [21]	Final Ischemic Stroke Lesions	U-Net	Minimal (n = 32): DSC=0.58(0.31-0.67) Major (n = 67): DSC= 0.48 (0.29-0.65)
Hyuna Lee, 2020 [22]	Stroke	Logistic regression SVM Random Forest	Sensitivity Logistic Regression = 75.8%, p: 0.02 SVM = 72.7%, p: 0.033 Random Forest = 75.8%, p: 0.013
Yusuf Kenan Cetinoglu 2021 [11]	Hemorrhagic and Ischemic stroke	CNN Modified MobileNetV2 EfficientNet-B0	Modified MobileNetV2: 96% (κ : 0.92) - EfficientNet-B0: 93% (κ : 0.86)
Sercan Yalçın 2022 [23]	Brain Tumor Ischemic and hemorrhagic stroke	CNN D-UNet	Brain Tumor: Precision: 0.99, Accuracy: 0.989 Brain Stroke: Precision: 0.986, Accuracy: 0.985
Adriell Gomes Marques 2022 [24]	Hemorrhagic stroke segmentation	Mask R-CNN Fine-tuning	Acc: 99.72 \pm 0.24 Sen: 99.97 \pm 0.06
Fathia ABOUDI, 2022 [25]	Ischemic Stroke	CNN U-Net Fine-tuning	Average precision: 99.77% Dice Coefficient: 55.77%
(Hongyu Gao 2023) [26]	Acute Ischemic Stroke (Endovascular Thrombectomy)	CNN SVM RF	CNN: CTP and PWI (0.902 vs. 0.928; p = 0.557)

V. CONCLUSION

In conclusion, this study found that the development of automated CAD systems for systematic stroke identification and measurement of stroke extent is necessary, which has significant therapeutic and diagnostic consequences. Eventually, this will result in better and more prompt stroke care, as well as lower patient morbidity and mortality. Advances in neuroimaging acquisition techniques, as well as the use of machine learning, are critical to this goal. In this review study, we conducted a thorough search for several image analysis approaches used to diagnose stroke lesions using MRI data. In this work, we looked at the most recent methods for segmenting and classifying cerebral stroke on MRI images, with an emphasis on machine learning approaches. This study found that by combining machine learning models and cognitive systems, brain infarcts may be recognized more efficiently and with greater accuracy on MRI in real-world clinical circumstances, which will aid in clinical

decision-making. Moreover, the limits of various methodologies as well as potential remedies are examined. We hope that this work will be a helpful resource for scholars in the subject as well as a source of ideas and inspiration.

ACKNOWLEDGMENT

The study is funded by Universiti Teknikal Malaysia Melaka (UTeM) through the Grant, No: PJP/2022/FTKKE/S01887. The authors are grateful for the facilities provided by Universiti Teknikal Malaysia Melaka (UTeM), Fakulti Kejuruteraan Elektrik (FKE), Fakulti Teknologi Kejuruteraan Elektrik & Elektronik (FTKKE), Advanced Digital Signal Processing (ADSP) Research Laboratory for all the supports.

REFERENCES

- [1] N. V. Kay Sin Tan, "Stroke Burden in Malaysia," *Cerebrovasc Dis Extra*, pp. 58-62, 2022.
- [2] A. Zainuddin, "CodeBlue Health is a human right: Malaysian Stroke Patients Take Average Seven Hours For Hospital Arrival," 28 December 2022. [Online]. Available: <https://codeblue.galencentre.org/2022/12/28/malaysian-stroke-patients-take-average-seven-hours-for-hospital-arrival/>.
- [3] E. M. S. T. H. R. B. A. M. N. M. M. A. A. A. T. S. A. a. F. A. G. Zeyad Ghaleb Al-Mekhlafi, "Deep Learning and Machine Learning for Early Detection of Stroke and," *Computers, Materials & Continua*, vol. 72, no. 1, p. 776, 2022.
- [4] U. R. ., A. G. ., Y. C. A. H. R. M. P. B. E. E. P. K. H. C. W. Y. C. J. C. R. A. Mahesh Anil Inamdar, "A Review on Computer Aided Diagnosis of Acute Brain Stroke," *Sensor*, pp. 1-35, 2021.
- [5] A. S. A. M. E. a. A. S. Nouf Saeed Alotaibi, "Detection of Ischemic Stroke Tissue Fate from the MRI Images Using a Deep Learning Approach," *Mobile Information Systems*, vol. 2022, pp. 1-11, 2022.
- [6] S. G. H. J. N. G. H. P. F. L. P. K. L. C. K. D. M. M. S. a. J. B. Jonathan Kottlors, "Contrast-Enhanced Black Blood MRI Sequence Is Superior to," *Diagnosis*, vol. 11, no. 1016, pp. 1-9, 2021.
- [7] B. Y. T. R. K. N. Surya.S, "A Comprehensive Method for Identification of Stroke using Deep Learning," *Turkish Journal of Computer and Mathematics Education*, vol. 12, no. 7, pp. 647-652, 2021.
- [8] B. K. B. K. K. S. E. P. Sung-Hye You, "Fast MRI in Acute Ischemic Stroke: Applications of MRI Acceleration Techniques for MR-Based Comprehensive Stroke Imaging," *iMRI*, no. 25, pp. 81-92, 2021.
- [9] I. T. K. T. P. a. S. S. Pragati Kakkar, "Current approaches and advances in the imaging of stroke," *Disease models & Mechanism*, vol. 14, no. 12, 2021.
- [10] P. D. ., M. M. R.-S. T. U. R. A. a. S. S. Asit Subudhi, "Application of Machine Learning Techniques for Characterization of Ischemic Stroke with MRI Images: A Review," *Diagnosis*, vol. 12, no. 2535, 2022.
- [11] *. I. O. K. ., M. E. U. ., M. F. G. Yusuf Kenan Cetinoglu, "Detection and vascular territorial classification of stroke on diffusion-weighted MRI by deep learning," *European Journal of Radiology*, vol. 145, no. 110050, pp. 1-8, 2021.
- [12] J. P. D. P. d. S. C. H. a. S. N. Yahia Mokli, "Computer-aided imaging analysis in acute," *Neurological Research and Practice*, pp. 1-13, 2019.
- [13] N. S. M. N. A. R. A. Norhashimah Mohd Saad, "A Review on Image Segmentation Techniques for MRI Brain Stroke Lesion," *JTEC* 6145, pp. 27-34, 2021.
- [14] F. W. L. Z. a. G. L. Haoliang Su, "Fuzzy Clustering Algorithm-Segmented MRI Images in Analysis of Effects of Mental Imagery on Neurorehabilitation of Stroke Patients," *Hindawi*, pp. 1-10, 2021.
- [15] K. K. ., A. T. J. M. H. M. S. K. S. A. T. H. a. S. H. Abang Mohd Arif Anaqi Abang Isa, "Pseudo-colour with K-means Clustering Algorithm for Acute Ischemic Stroke Lesion Segmentation in Brain MRI," *Pertanika J. Sci. & Technology*, pp. 743-758, 2021.
- [16] V. R. S. S. V. S. Prof. Kavita Bathe, "Brain Tumor Detection Using Deep Learning Techniques," in 4th International Conference on Advances in Science & Technology (ICAST2021), Mumbai, India, 2021.
- [17] D. David, "Random Forest Classifier Tutorial: How to Use Tree-Based Algorithms for Machine Learning," 6 August 2020. [Online]. Available: <https://www.freecodecamp.org/news/how-to-use-the-tree-based-algorithm-for-machine-learning/>.
- [18] Q. L. F. S. I. R. Z. P. Gaoxiang Chen, "RFDCR: Automated brain lesion segmentation using cascaded random forests with dense conditional random fields," *Elsevier Neurimage*, pp. 1-14, 2020.
- [19] TIBCO, "What is a Random Forest?," 2023. [Online]. Available: <https://www.tibco.com/reference-center/what-is-a-random-forest>.
- [20] S. X. L. T. H. W. ., a. J. M. Shujun Zhang, "Stroke Lesion Detection and Analysis in MRI Images Based on Deep Learning," *Journal of Healthcare Engineering*, vol. 2021, pp. 1-9, 2021.
- [21] M. Yannan Yu, M. Yuan Xie, T. Thamm, P. Enhao Gong, M. Jiahong Ouyang, B. Charles Huang, P. Soren Christensen, M. Michael P. Marks, M. Maarten G. Lansberg, M. Gregory W. Albers and M. P. Greg Zaharchuk, "Use of Deep Learning to Predict Final Ischemic Stroke Lesions From Initial Magnetic Resonance Imaging," *JAMA Network Open*, vol. 3, no. 3, pp. 1-13, 2020.
- [22] P. E.-J. L. M. S. H. M. H.-B. L. M. J. S. L. P. S. U. K. M. J. S. K. M. N. K. P. D.-W. K. M. Hyunna Lee, "Machine Learning Approach to Identify Stroke Within 4.5 Hours," *STROKEAHA Journal*, vol. 51, no. 3, 2020.
- [23] H. V. Sercan Yalçın, "Brain stroke classification and segmentation using encoder-decoder based deep convolutional neural networks," *ELSEVIER (Computer in Biology and Medicine)*, pp. 1-14, 2022.
- [24] L. F. d. F. S. J. J. d. C. N. I. B. L. I. C. L. S. Adrieli Gomes Marques, "Automatic Segmentation of Hemorrhagic Stroke on Brain CT Images Using Convolutional Neural Networks Through Fine-Tuning," in 2022 International Joint Conference on Neural Networks (IJCNN), Padua, Itali, 2022.
- [25] 2. ., C. D. a. T. K. Fathia ABOUDI1, "Efficient U-Net CNN with data augmentation for MRI ischemic stroke brain segmentation," 2022 8th International Conference on Control, Decision and Information Technologies, vol. CoDIT'22, pp. 724-728, 2022.
- [26] Y. B. G. C. H. Y. Y. C. H. Z. J. W. Q. L. Q. Y. a. L. W. Hongyu Gao, "Identifying patients with acute ischemic stroke within a 6-h window for the treatment of endovascular thrombectomy using deep learning and perfusion imaging," *Frontiers in Medicine*, pp. 1-8, 2023.
- [27] T. E. T. K. H. S. D. H. S. H. B. Y. W. P. H.-J. L. B. W. C. & S. S. A. Yohan Jun, "Deep-learned 3D black-blood imaging using automatic labelling technique and 3D convolutional neural networks for detecting metastatic brain tumors," *Scientific Reports*, pp. 1-11, 2018.
- [28] D. R. S. S. Bhagyashree Rajendra Gaidhani, "Brain Stroke Detection Using Convolutional Neural Network and Deep Learning Models," in 2019 2nd International Conference on Intelligent Communication and Computational Techniques (ICCT), Manipal University Jaipur, 2019.
- [29] P. ., H. K. P. ., E. T. M. ., J. M. O. M. ., S. I. S. P. M. ., Wu Qiu, "Machine Learning for Detecting Early Infarction in Acute Stroke with Non-Contrast-enhanced CT," *Radiology*, vol. 294, pp. 638-644, 2020.
- [30] P. H. V. M. M. R. S. S. I. L. A. E. T. S. F. C. J. C. S. R. & I. Carlos Fernandez Lozano, "Random forest based prediction," *Scientific Reports*, vol. 11, no. 10071, pp. 1-12, 2021.
- [31] J. H. X. X. S. R. V. W. M. I. M. A. E. H. A. V. F. & T. S. a. V. I. i. Chin-Fu Liu, "Deep learning-based detection and segmentation of diffusion abnormalities in acute ischemic stroke," *Communications Medicine*, pp. 1-18, 2021.
- [32] S. J. a. S. S. A. Subudhi, "Delineation of the ischemic stroke lesion based on watershed and relative fuzzy connectedness in brain MRI," *Med. Biol. Eng. Comput.*, vol. 56, no. 5, pp. 795-807, 2018.

© 2023. This work is licensed under <http://creativecommons.org/licenses/by/4.0/> (the “License”). Notwithstanding the ProQuest Terms and Conditions, you may use this content in accordance with the terms of the License.